

The Neuroscientist

<http://nro.sagepub.com/>

The Language Connectome: New Pathways, New Concepts

Anthony Steven Dick, Byron Bernal and Pascale Tremblay

Neuroscientist published online 15 December 2013

DOI: 10.1177/1073858413513502

The online version of this article can be found at:

<http://nro.sagepub.com/content/early/2013/12/11/1073858413513502>

Published by:



<http://www.sagepublications.com>

Additional services and information for *The Neuroscientist* can be found at:

Email Alerts: <http://nro.sagepub.com/cgi/alerts>

Subscriptions: <http://nro.sagepub.com/subscriptions>

Reprints: <http://www.sagepub.com/journalsReprints.nav>

Permissions: <http://www.sagepub.com/journalsPermissions.nav>

>> [OnlineFirst Version of Record](#) - Dec 15, 2013

[What is This?](#)

The Language Connectome: New Pathways, New Concepts

The Neuroscientist
201X, Vol XX(X) 1–15
© The Author(s) 2013
Reprints and permissions:
sagepub.com/journalsPermissions.nav
DOI: 10.1177/1073858413513502
nro.sagepub.com



Anthony Steven Dick¹, Byron Bernal², and Pascale Tremblay³

Abstract

The field of the neurobiology of language is experiencing a paradigm shift in which the predominant Broca–Wernicke–Geschwind language model is being revised in favor of models that acknowledge that language is processed within a distributed cortical and subcortical system. While it is important to identify the brain regions that are part of this system, it is equally important to establish the anatomical connectivity supporting their functional interactions. The most promising framework moving forward is one in which language is processed via two interacting “streams”—a dorsal and ventral stream—anchored by long association fiber pathways, namely the superior longitudinal fasciculus/arcuate fasciculus, uncinate fasciculus, inferior longitudinal fasciculus, inferior fronto-occipital fasciculus, and two less well-established pathways, the middle longitudinal fasciculus and extreme capsule. In this article, we review the most up-to-date literature on the anatomical connectivity and function of these pathways. We also review and emphasize the importance of the often overlooked cortico-subcortical connectivity for speech via the “motor stream” and associated fiber systems, including a recently identified cortical association tract, the frontal aslant tract. These pathways anchor the distributed cortical and subcortical systems that implement speech and language in the human brain.

Keywords

language, arcuate fasciculus, white matter, dorsal stream, ventral stream, motor stream, cortico-striatal loops, cortico-bulbar tract

Introduction

The field of the neurobiology of language is experiencing a paradigm shift (Poepfel and others 2012). In stark contrast to the “left hemisphere” Broca–Wernicke–Geschwind model of language that has dominated the field for more than 100 years, functional neuroimaging studies of the past decade have provided evidence that large parts of the left and right perisylvian cortex, in collaboration with an extensive cortico-subcortical network to process language, contribute to speech and language functions. In addition to functional imaging evidence, there is a renewed interest not just on the regions that comprise the distributed language network but also in how those regions communicate via bundled fiber pathways. Putatively organized along ventral and dorsal processing streams, these pathways are more extensive than previously supposed and include tracts beyond the arcuate fasciculus of the classic model, some long established and others more recently described. In this article, we review the anatomy and proposed functionality of these tracts. In addition, we make a plea to extend contemporary models of language neurobiology to include the fibers of the corticobulbar tract, the basal ganglia–cortical connections, and the cortico-cerebellar-cortical loop,

which form an extended “motor stream.” It is within this framework that the field will continue to make promising strides toward a comprehensive neurobiology of language.

Classic and Contemporary Models of Language Connectivity

The classic model of language connectivity is summarized by Geschwind (1970), but his treatment is an expansion of the classical Broca–Wernicke–Lichtheim model from the late 19th century. In its most simplified form, the model consists of an anterior *Broca’s area* consisting of the posterior two thirds of the inferior frontal gyrus; a

¹Department of Psychology, Florida International University, Miami, FL, USA

²Department of Radiology, Miami Children’s Hospital, Miami, FL, USA

³Université Laval and Centre de Recherche de l’Institut Universitaire en Santé mentale de Québec, Québec, Canada

Corresponding Author:

Anthony Steven Dick, Department of Psychology, Florida International University, Modesto A. Maidique Campus, Academic Health Center-4 454, 11200 S.W. 8th Street, Miami, FL 33199, USA.
Email: adick@fiu.edu

posterior *Wernicke's area*, consisting of the posterior superior temporal gyrus, and in some cases the surrounding cortex of the superior temporal sulcus, inferior parietal lobule and posterior middle temporal gyrus; and the arcuate fasciculus (AF; often referred to as synonymous with the superior longitudinal fasciculus [SLF]) connecting these regions.

This classic model has surprising resilience despite the general agreement among scientists that it is overly simplistic (Poeppel and others 2012). Part of this resilience stems from the fact that the model still serves a reasonable heuristic value for the evaluation and treatment of acquired language disorders. However, a significant reason for its continued use, especially in introductory scientific and medical textbooks, is that there has not been a clear replacement for the classic model, though models with a dual-stream "dorsal-ventral" architecture analogous to that of the visual system have emerged as potential replacements (Hickok and Poeppel 2007; Rauschecker and Scott 2009). Within the dorsal stream, fronto-temporo-parietal regions are proposed to be involved in mapping auditory speech sounds to articulatory (motor) representations, and also in processing complex syntactic structures. The major fiber pathway proposed to connect these regions is the SLF/AF. In contrast, the ventral stream is proposed to be involved in mapping auditory speech sounds to meaning, or in processing less complex syntactic structure. The fiber pathways that have been proposed to anchor the ventral stream are the uncinate fasciculus (UF), the extreme capsule (EmC), the middle longitudinal fasciculus (MdLF), the inferior longitudinal fasciculus (ILF), and the inferior fronto-occipital fasciculus (IFOF). In addition to these pathways, understanding the white matter connectivity of language requires an understanding of several other tracts whose organization has also been shown to be far more complex than previously believed: these include the descending pyramidal system, the cortico-striatal loops as well as long association fibers connecting inferior frontal and premotor regions of the frontal lobe, and the cortico-cerebellar system.

Dorsal Streams: Anatomy and Function

Superior Longitudinal Fasciculus/Arcuate Fasciculus: Anatomy

Despite its prominence for the neurobiology of language, the precise course, origins, and terminations of the SLF/AF pathway remain a matter of contention. Several models of SLF/AF connectivity exist in the contemporary literature. The main areas of contention center around three issues: (1) whether there exists direct frontal-temporal

connectivity via this pathway, (2) the determination of the exact rostral (frontal) origins/terminations of the tract, and (3) determination of the caudal (temporal) origins/terminations of the tract.

Direct temporal-frontal connectivity via the SLF/AF was controversial in the mid-to-late 19th century, but in the latter part of the 20th century, the field uncritically accepted the notion that the SLF/AF has rostral terminations in the inferior frontal gyrus (Broca's area) and caudal terminations in the posterior superior temporal gyrus (Wernicke's area). Déjérine (1901) also suggested a caudal connection to the angular gyrus, and this is the model that Geschwind (1970) consolidated in the latter part of the 20th century. However, these anatomical models are based on postmortem dissection methods that are not ideal for identifying the precise course of the fiber pathways under study (Schmahmann and Pandya 2006). It is for this reason that more recent investigators have reexamined the connectivity of the SLF/AF.

Histological tract tracing methods unavailable for research in humans can be used to examine connectivity in animals, particularly the macaque. The majority of these studies, using autoradiographic tract tracing for more precise determination of pathway origins and terminations, have suggested that there is no direct connection between the posterior superior temporal gyrus (i.e., Wernicke's area homologue) and the inferior frontal gyrus (i.e., Broca's area homologue). Such data have further suggested that the SLF/AF itself can be separated into four subcomponents and the AF (Schmahmann and Pandya 2006; Yeterian and others 2012, for review).

The SLF III and AF components have received the most attention for language. In the macaque, the SLF III connects the anterior inferior parietal lobule with the ventral premotor and posterior inferior frontal gyrus. The AF component, however, appears to connect the posterior superior temporal gyrus with more dorsal premotor and lateral prefrontal cortex (areas 9/46d, 8Ad, and 6d), and not to the inferior frontal gyrus (Schmahmann and Pandya 2006; see Petrides and Pandya 2009, for an exception). In summary, while there is evidence for inferior parietal and inferior frontal connectivity via the SLF III, a connection between posterior temporal and inferior frontal cortex appears to be absent in the macaque.

In the human, diffusion tensor imaging (DTI) and blunt fiber dissection work conducted over the last few years has offered several alternative models of dorsal stream connectivity via the SLF/AF. Figure 1 presents four summaries of different contemporary DTI-based models, overlaid on a blunt fiber dissection of the lateral surface from Ludwig and Klingler (1956). Figure 1A presents the connectivity profile of the SLF III and AF described in the macaque and explored in the human (Bernal and Altman 2010; Brown and others 2013; Makris and others 2005).

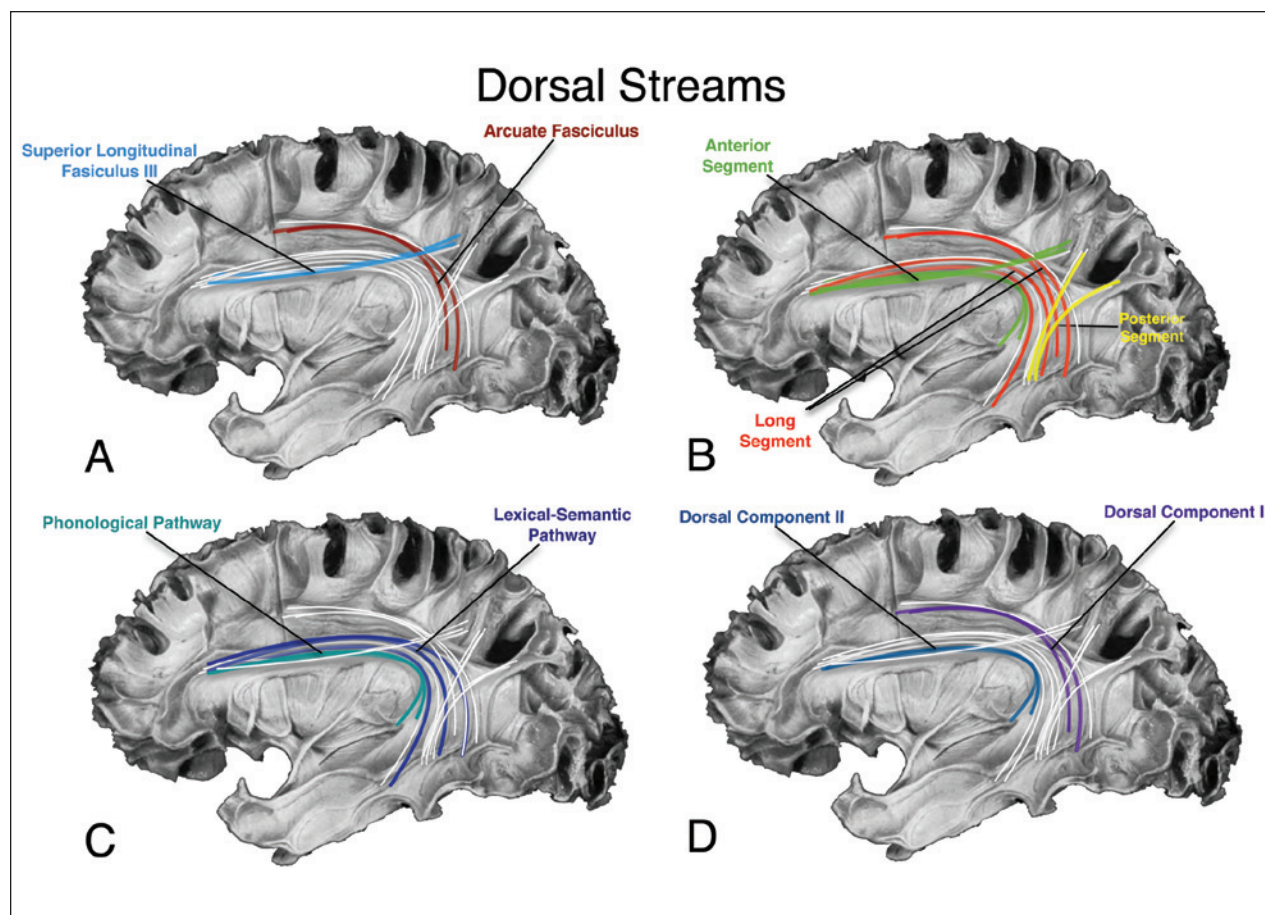


Figure 1. Competing views of the dorsal streams. Competing models of dorsal stream connectivity overlaid on a dissection by Ludwig and Klingler (1956; Table 6). The different models emphasize different aspects of the superior longitudinal fasciculus/arcuate fasciculus (SLF/AF) complex. (A) A “three-segment” model presented by Catani and others (2005). (B) A “two-segment” model presented by Glasser and Rilling (2008). (C) A “two-segment” model from Makris and others (2005) and influenced by work in the macaque (Schmahmann & Pandya 2006). (D) A “two-segment” model proposed by Friederici and colleagues (Brauer and others 2013; Perani and others 2011).

The SLF III is the main pathway of posterior inferior frontal gyrus connectivity with the supramarginal gyrus, and the temporal lobe projects to more posterior and premotor cortex via the AF component.

Figure 1B presents Catani’s 2005 model of the SLF/AF (Catani and others 2005; Thiebaut de Schotten and others 2012). The “long segment” connects the temporal and posterior frontal lobe. Specifically, their tractography suggests posterior superior temporal gyrus projections to the inferior frontal gyrus (*pars triangularis* and *pars opercularis*). Middle and inferior temporal gyrus connections are also shown to project to the inferior frontal gyrus and the more ventral precentral gyrus. Two “indirect” segments contribute additional connectivity. The anterior part constitutes a fronto-inferior parietal–posterior temporal segment (consistent with the SLF III; Thiebaut de Schotten and others 2012), and a posterior part constitutes a posterior temporal–inferior parietal segment.

Martino and others (2013) attempted to verify this connectivity profile with combined DTI and blunt fiber dissection, and they reported a broadly similar connectivity profile, although the latter group reports more prominent connectivity with the middle and inferior temporal gyrus to parietal and frontal cortex.

Figure 1C shows the connectivity profile identified by Glasser and Rilling (2008). They propose a two-segment model with a middle temporal–inferior frontal “lexico-semantic” segment, and a superior temporal–inferior frontal “phonological” segment, predominantly in the left hemisphere (the right hemisphere has a similar connectivity, but with a different proposed linguistic function—that of prosody). Notably, the connections to the more dorsal premotor cortex, and to the inferior parietal cortex, are absent in this model.

Figure 1D presents the model by Friederici and others (Brauer and others 2013; Perani and others 2011), who

suggest two dorsal pathways. One projects from the posterior temporal cortex to the premotor cortex involved in sensorimotor function, and the other projects from the posterior temporal cortex to the posterior inferior frontal gyrus, involved in syntactic processing.

In summary, the precise anatomical characterization of the SLF/AF fiber pathway remains under investigation, although it has undergone a major revision in the last few years, which has served to frame investigations of the function of these perisylvian pathways. We turn now to a discussion of these studies and the function of the dorsal SLF/AF pathways.

Superior Longitudinal Fasciculus/Arcuate Fasciculus: Function

Historically, it has been suggested that the function of the SLF/AF is to transfer information between Wernicke's and Broca's areas (Geschwind 1970), but this connectivity profile has been called into question. Importantly, the arcuate component may target the inferior premotor cortex, corresponding to agranular BA 6, rather than the inferior frontal gyrus, which has important implications in terms of its potential role (Bernal and Altman 2010; Brown and others 2013). Early functional notions of the SLF/AF have emphasized its role in verbal repetition and the syndrome associated with its lesion, conduction aphasia (see Ardila 2010; Bernal and Ardila 2009, for reviews). Damage to the SLF/AF is associated with deficits in fluency (Breier and others 2008; Marchina and others 2011), but this is often associated with cortical lesion as well. In fact, there are few if any documented cases of conduction aphasia following focal lesion to the SLF/AF (Tanabe and others 1987), and even agenesis of the SLF/AF does not result in conduction aphasia (Bernal and others 2010). However, the pathway may play a more general role in phonological processing. For example, electrical stimulation of the SLF/AF results in speech arrest (Duffau and others 2002; Duffau and others 2003; Maldonado and others 2011) and phonemic paraphasias (Duffau and others 2002; Mandonnet and others 2007), and it may be an important pathway in language learning (Bernal and Ardila 2009; Bernal and others 2010)—integrity of this tract predicts phonological and reading skills in children (Yeatman and others 2011).

The SLF/AF has also been proposed to be involved in processing complex syntactic structures during language comprehension (Brauer and others 2013; Friederici and others 2006). For example, Wilson and others (2011) showed that integrity of the SLF/AF is associated with deficits in syntactic production and comprehension in people with primary progressive aphasia.

In summary, with the revision of the classical model there is renewed interest in understanding the dorsal

language pathways of the SLF/AF. Emerging evidence suggests a role for this pathway in processing phonological information and complex syntax during language comprehension and speech production.

Summary of the Dorsal Stream

The major fiber tract anchoring the dorsal stream is the SLF/AF. Despite the historical interest in this pathway, its anatomical connectivity profile remains to be definitively established, and there are several competing models of its connectivity. Critically, this uncertainty regarding the anatomy of the pathway impedes our understanding of its function. Emerging evidence, though, seems to point to the importance of this pathway for processing phonology and syntax during speech production and comprehension.

Ventral Streams: Anatomy and Function

Uncinate Fasciculus: Anatomy

Recent reviews of the UF present an updated understanding of the connectivity of this fiber pathway (Thiebaut de Schotten and others 2012; Von Der Heide and others 2013). The extant research suggests a rostral termination projecting to the orbital and lateral frontal cortex, to the frontal pole, and to the anterior cingulate gyrus (mainly BAs 10, 11, 32, and 47). The posterior termination in the temporal lobe appears to include projections through the amygdala, with terminations in the temporal pole (BA 38), uncus (BA 35), and parahippocampal gyrus (BA 30 and 36; Holl and others 2011).

Uncinate Fasciculus: Function

The UF has been proposed to be involved in semantic memory retrieval/processing, although its role in language remains controversial (Von Der Heide and others 2013). Some researchers question the role of the UF in language processing because of the proposed connectivity to ventral and orbital portions of the frontal lobe, which are not typically associated with language functions. The proposed involvement in semantic processing is suggested by the putative functions of the anterior temporal lobe and the temporal pole, regions thought to comprise a semantic "hub" as part of a anterior temporal lobe semantic system (Holland and Lambon Ralph 2010). However, whether the temporal pole is essential for semantic processing is also a contentious issue. While some research shows evidence for semantic disturbance following resection or electrostimulation of the anterior temporal lobe and UF (Papagno and others 2011), others

fail to show that resection of the temporal pole reliably results in significant semantic disturbance (Kho and others 2008; Moritz-Gasser and others 2013).

Imaging work tends to support semantic function of the UF fiber pathway. A few studies have shown that DTI measures of white matter integrity of the UF are associated with semantic dementia and/or the semantic variant subtype of primary progressive aphasia (Agosta and others 2013). Finally, some data have suggested the involvement of the UF in basic syntactic processing (Friederici and others 2006). In summary, supportive evidence for the involvement of the UF in semantic processing continues to emerge, but it is inconsistent. Further evidence showing a syntactic function of the UF would also provide support for the pathway's involvement in language.

Extreme Capsule: Anatomy

The main fibers of the EmC run between the claustrum and insula, lateral and parallel to the internal and external capsules, but whether these should be considered fibers of a dissociable tract in the human is a matter of controversy. Historically, the EmC is considered a location in the brain rather than a distinct collection of association fibers. For example, Déjèrine (1895) suggested that the EmC contains association fibers, and he distinguished this tract from the UF and ILF, but he also suggested that the EmC was comprised partly of fibers of the external capsule, and did not list it among the most prominent *long faisceaux d'association*. Several authors locate the fibers traveling as part of the IFOF in the EmC (Catani and de Schotten 2012; Duffau and others 2013; Oishi and others 2011; Thiebaut de Schotten and others 2012). Other researchers use the less-specific term "extreme capsule fiber system" (Griffiths and others 2013; Perani and others 2011).

The renewed focus on the EmC as a long association fiber pathway originates from work conducted in the macaque. Autoradiography studies suggest a specific connectivity, with bidirectional pathways between the anterior, middle, and posterior superior temporal lobe, and the posterior and ventral and lateral prefrontal cortex (Schmahmann and Pandya 2006).

Several DTI studies have been conducted to establish the connectivity of the EmC. Makris and Pandya (2009) dissociated the EmC from the UF and ILF, and suggest that this pathway also terminates posteriorly in the angular gyrus. This is a much more posterior termination than that suggested by the data in the macaque, and by other DTI studies of the EmC fiber pathway (Saur and others 2008). However, it is notable that the white matter comprising the EmC between the insula and the claustrum is below the imaging resolution of most DTI studies. Thus, many authors suggest that the fibers are passing through

the EmC, but do not identify them as EmC fibers because they cannot be reliably dissociated from other fibers passing through that region (e.g., the UF and IFOF; Thiebaut de Schotten and others 2012). Methodological advances will help resolve these issues.

Extreme Capsule: Function

A difficulty with identifying the functions of the EmC is related to the difficulty of dissociating EmC fibers from neighboring UF and IFOF fibers. Thus, there are few studies focusing exclusively on EmC fiber pathway function. For those studies that do, the EmC is proposed to connect anterior inferior frontal gyrus with the middle to posterior portions of the superior and middle temporal cortex. The anterior inferior frontal gyrus and posterior superior and middle temporal cortices are associated with controlled retrieval of semantic representations or during long-term lexical storage (Lau and others 2008). Connectivity among these regions would comprise a prominent component of the ventral language stream. This was suggested by Saur and others (2008) based on fiber tractography using regions that were active during the repetition of pseudowords and during the comprehension of sentences as seeds for the tractography. While repetition seemed to rely on dorsal pathways through the SLF/AF, fibers traveling through the EmC were associated with sentence comprehension.

The EmC fibers may also subserve more basic semantic functions. For example, electrostimulation of fibers passing through the EmC elicits semantic paraphasias (Duffau and others 2005), although Duffau and others (2013) identify these fibers as part of the IFOF. Finally, some data suggest that in addition to semantic processing, fibers of the EmC participate in syntactic processing (Griffiths and others 2013). In a study of 24 chronic stroke patients, Rolheiser and others (2011) reported that, in addition to a cluster in the posterior part of the AF, comprehension of syntax correlated with integrity of the posterior part of the EmC, suggesting that both pathways participated in syntactic processing.

In summary, both the anatomy and functionality of the EmC remains elusive. If it is a separate fiber bundle, in addition to syntactic processing, the EmC may participate in semantic functions usually attributed to the adjacent IFOF and UF fibers. Therefore, progress on the functional characterization of the EmC is intimately tied to progress on the anatomical characterization of the pathway.

Middle Longitudinal Fasciculus: Anatomy

The MdLF does not appear in classic neuroanatomy texts and was originally described by Seltzer and Pandya

(1984) in the macaque. In their original study, injection of radiolabeled isotope in the caudal third of the macaque inferior parietal lobule (homologous to the human angular gyrus and lower bank of the intraparietal sulcus) revealed axonal terminations along the superior temporal gyrus and sulcus with rostral terminations in the anterior temporal lobe. Thus, the fiber pathway connects the caudal and inferior parietal lobe with the superior temporal lobe, with terminations running rostrally and intermittently along the course of the superior temporal lobe. Subsequent studies in the macaque have replicated these findings, and have also distinguished the MdLF from the ILF, SLF, and AF pathways (see Schmahmann and Pandya 2006, for review).

While the existence of the MdLF is uncontroversial in the macaque, the relative lack of research on this particular tract in the human has made it difficult to establish consensus. Fortunately, interest in and research on the MdLF in the human has increased significantly over the past five years. DTI studies (Makris and others 2009; Saur and others 2008; Turken and Dronkers 2011; Wong and others 2011) suggest that the posterior course of the MdLF in the human runs medial to the SLF/AF, originating in the angular gyrus and terminating in the anterior superior temporal gyrus and sulcus, with some evidence for terminations in the temporal pole. Makris (Makris and others 2013a; Makris and others 2013b) conducted two additional DTI studies that have largely confirmed the earlier results regarding the course of the tract in the temporal lobe with terminations in the angular gyrus. However, their data and that reported by others (Maldonado and others 2013; Menjot de Champfleury and others 2013; Wang and others 2012) also suggest that at least some of the caudal terminations are more posterior than the previously reported terminations in angular gyrus. In an analysis of 74 people using high-angular-resolution diffusion imaging (HARDI), Makris and others (2013b) provided evidence for two caudal terminations of the MdLF—one in the angular gyrus and the other in the superior parietal lobule. In contrast, Maldonado and others (2013), based on a fiber dissection study of 18 post-mortem human brains, suggest that there is no termination of MdLF fibers in the angular gyrus (also see Wang and others 2012). In this study, the MdLF was dissociated from the AF and IFOF in the white matter of the superior temporal gyrus, and results demonstrate that the caudal termination of the MdLF continues posterior to the angular gyrus to terminate in the dorsal portions of the occipital lobe and the inferior lip of the parieto-occipital arcus. Temporal connections with the angular gyrus were found but they were attributed to the SLF/AF fiber pathway instead of the MdLF pathway (also see Martino and others, 2013). Though in need of replication, the findings of a lack of connectivity with the angular gyrus could have profound implications for the role of the MdLF,

suggesting that the MdLF is not a core language pathway (cf. De Witt Hamer and others 2011).

Middle Longitudinal Fasciculus: Function

The status of the MdLF with respect to language function is unclear. Limited evidence suggests that the MdLF functions as part of a ventral sound-to-meaning pathway (Saur and others 2008; Wong and others 2011) or as part of a network for language comprehension (Turken and Dronkers 2011). Schmahmann and Pandya (2006) identified it as one of three long association pathways likely to play a role in language. In contrast, others claim that the MdLF is not essential for language (De Witt Hamer and others 2011; Duffau and others 2013). For example, De Witt Hamer and others (2011) were unable to elicit semantic paraphasias during electrostimulation of this tract, although they were able to do so stimulating the IFOF. Furthermore, neither electrostimulation nor resection of the anterior part of MdLF had any effect on picture naming, which challenges a contribution to semantic processing. In summary, given the limited and conflicting empirical evidence, it is premature to decide on the status of the MdLF as a pathway supporting language function.

The Inferior Longitudinal Fasciculus and Inferior Fronto-Occipital Fasciculus: Anatomy

The ILF and IFOF fiber pathways are two long association pathways that are proposed to connect the occipital lobe with the anterior temporal and the frontal lobes, respectively. However, there remains disagreement about the rostral termination of those fibers (either in the frontal or temporal lobe), and whether there are two dissociable fiber tracts (ILF and IFOF) or just one.

The earliest specific identification of an ILF originates from Burdach who identified a fiber tract running uninterrupted from the occipital lobes to the lateral cortex of the frontal pole (see Forkel and others 2012, for review). For reasons that are unclear, this description did not have a prominent impact on the literature at the time. For example, Déjèrine located the ILF rostral terminations in the temporal pole (not the frontal pole), and did not distinguish a separate IFOF coursing in the temporal lobe. The formal establishment of the IFOF as an independent pathway waited until the early twentieth century (Forkel and others 2012).

Although the IFOF cannot be identified in the macaque (Schmahmann and Pandya 2006), DTI studies consistently identify both an ILF and an IFOF in humans (Catani and Thiebaut de Schotten 2012; Oishi and others 2011). Still, the establishment of the precise course of the ILF and IFOF awaits further validation with continued developments in DTI methodology (Forkel and others 2012; Holl and others 2011; Sarubbo and others 2013)

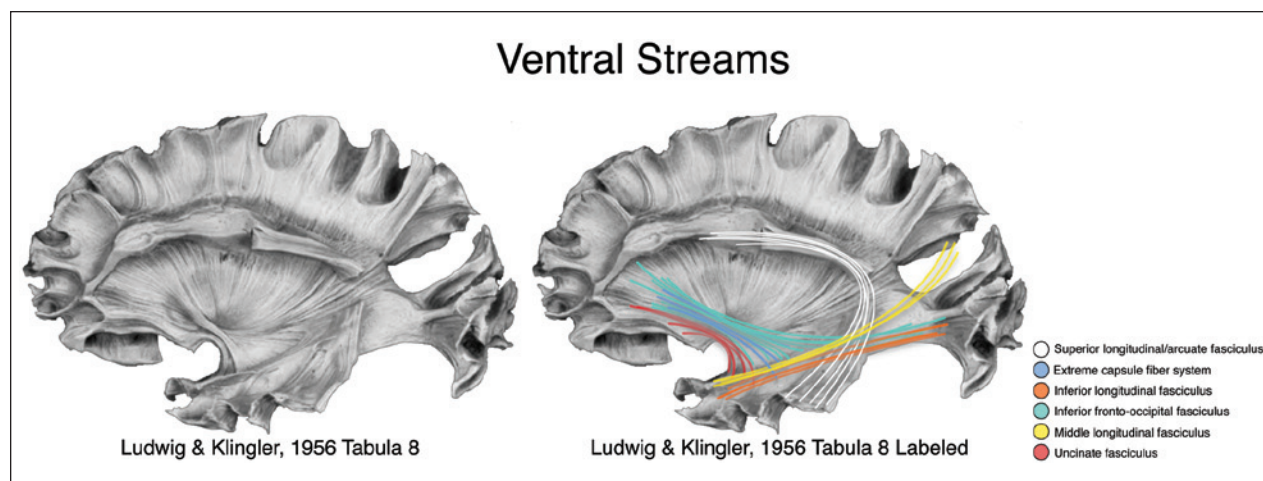


Figure 2. The ventral streams. Pathways of the ventral stream overlaid on a dissection by Ludwig and Klingler (1956; Table 8). The left figure is unlabeled; the right is the same brain labeled with the pathways. Superior longitudinal fasciculus/arcuate fasciculus (SLF/AF) connectivity of the dorsal stream is represented in white.

and in postmortem methods (Holl and others 2011; Martino and others 2010a; Sarubbo and others 2013). Nevertheless, based on these studies, a putative trajectory of both pathways can be proposed. The ILF connects the occipital lobe with the temporal lobe, originating in extrastriate areas with rostral terminations in the middle and inferior temporal gyri, the temporal pole, parahippocampal gyrus, hippocampus, and amygdala (Catani and others 2003). The IFOF runs medial to the ILF, originates in the inferior and medial occipital lobe (and possibly the medial parietal lobe), sends projections to the ventral temporal lobe, travels through the temporal stem dorsal to the UF, and projects to the inferior frontal gyrus, the medial and orbital frontal cortex, and the frontal pole (Catani and others 2003). In its anterior course it may be composed of two components (Martino and others 2010b; Sarubbo and others 2013). In some preparations, though, the precise rostral terminations are difficult to determine (Martino and others 2010b).

The Inferior Longitudinal Fasciculus and Inferior Fronto-Occipital Fasciculus: Function

Duffau and others (2013) have emphasized the IFOF as the main “direct” pathway subserving the ventral semantic system essential for semantic processing for language. This group has shown that electrostimulation of the IFOF at both anterior and posterior locations elicited semantic disturbances (Duffau and others 2005; Mandonnet and others 2007; Moritz-Gasser and others 2013). In this latter study, stimulation was conducted primarily at the point where the IFOF inflects to run superiorly into the frontal lobe. Duffau and others have postulated a second, indirect semantic pathway that includes the ILF and UF (Duffau and others 2013;

Moritz-Gasser and others 2013), but suggest this pathway is neither necessary nor sufficient for semantic processing in language.

The ILF has also been cited as a major component of the ventral semantic system for language, sometimes in collaboration with other temporal fiber pathways, including the IFOF (i.e., the UF, MdLF, and EmC; Agosta and others 2013; Turken and Dronkers 2011; Saur and others 2008; Wong and others 2011). A more recent empirical study sheds some light on the differing roles of the IFOF and ILF for language. In this electrostimulation study, Gil-Robles and others (2013) reported a double dissociation between stimulation of the ILF and the IFOF, where stimulation of the ILF induced visual object recognition and reading disturbance, but no picture naming impairment. In contrast, stimulation of the IFOF in the same subjects disturbed picture naming, but not visual object recognition or reading disturbance. This suggests that the IFOF may be more related to semantic processing, and the ILF more related to visual-orthographic processing (also see Fernández-Miranda and others 2008).

Summary of the Ventral Stream

Several pathways have been identified as part of the ventral language stream (Fig. 2). However, investigation of the function of the ventral pathways is somewhat impeded by the need to better define the anatomical connectivity of the pathways. The EmC and MdLF in particular require further study to determine whether they should be identified as independent fiber pathways dissociable from the other tracts of the ventral stream. Figure 3 summarizes the approximate distribution of the ventral and dorsal fiber pathways in the coronal view.

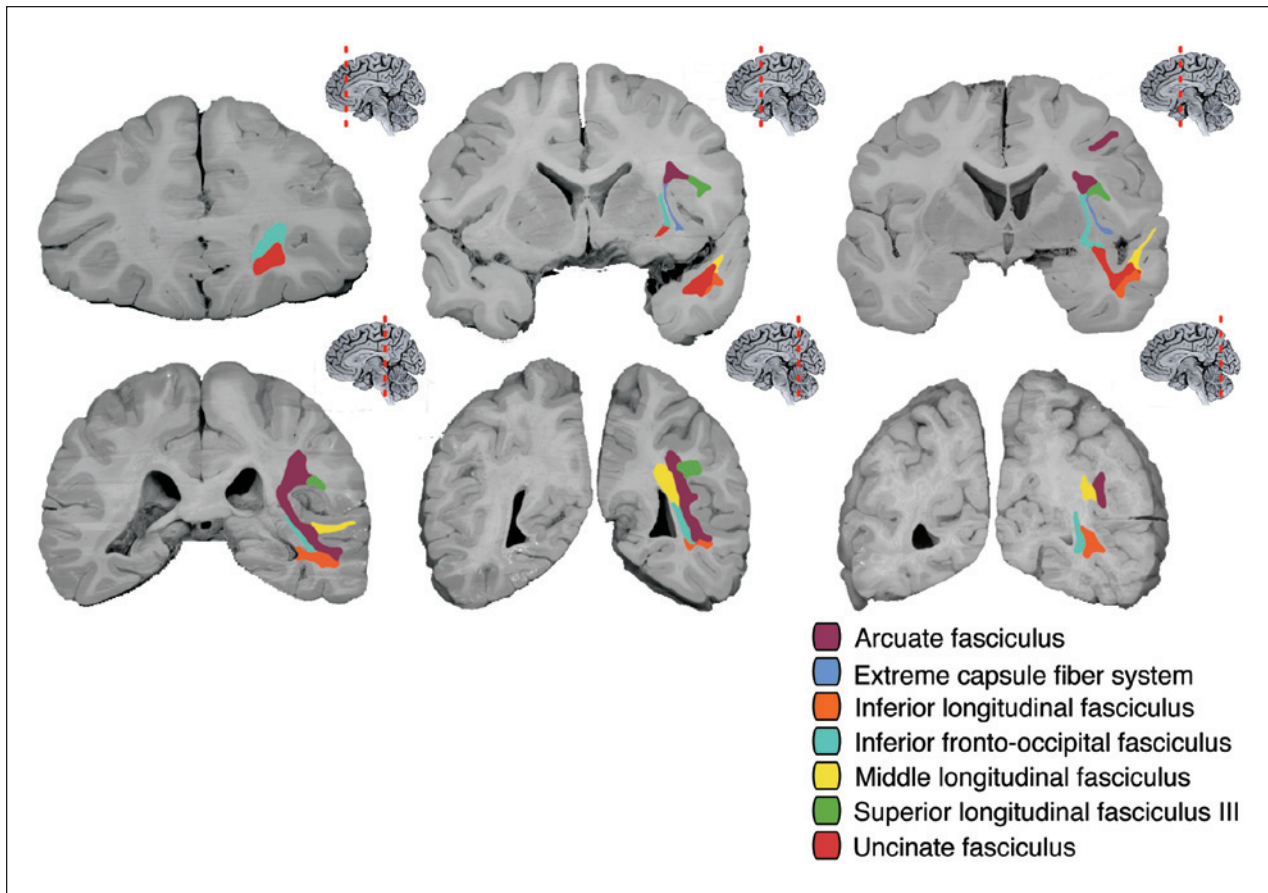


Figure 3. Summary of dorsal and ventral streams in coronal section. Locations are approximate and present an idealized distribution. In reality there is significant crossing and overlap of the fiber systems throughout their course.

The Motor Stream: Anatomy and Function

Contemporary neurobiological models of language do not typically tackle the issue of the manner in which speech motor commands are assembled and sent to more than 100 muscles involved in the act of speaking. Yet, the production of speech is a complex process that involves the control of supralaryngeal structures for articulation, the control of thoracic and abdominal muscles for the regulation of respiratory activity, and the control of intrinsic and extrinsic laryngeal muscles for the production of vocal folds vibration necessary to produce speech. It also requires the coordination of these systems with the neural systems underlying linguistic and cognitive/executive aspects of language production. Understanding this complex system thus requires basic knowledge of (1) the descending tracts, especially the corticobulbar pathway, (2) motor association pathways, and (3) the cortico-subcortical loops. This represents a significant revision of the view that the neurobiology of language can be understood in the context of the strictly a cortical classical language model.

Descending Pathways: Anatomy and Function

The primary motor cortex (M1), located in the central sulcus and precentral gyrus is the cortical region that projects the largest number of corticospinal and corticobulbar fibers. These fibers connect M1 to the motor nuclei located in the brainstem and spinal cord through the pyramidal system, one of the most important pathways for the control of voluntary movements. Neurons in M1 are organized in an imprecise somatotopic manner (Harrison and Murphy 2014), with the area controlling the face and larynx located ventrally. The control of speech relies primarily on the integrity of the corticobulbar tract (CBT; Fig. 4), a small division of the pyramidal system that connects the brain to motor nuclei of the cranial nerves located in the brainstem, which are responsible for the sensorimotor innervation of laryngeal and supralaryngeal muscles and are thus key to not only speaking and eating but also facial expressions (Jürgens 2002). The corticospinal tract (CST) contributes to the innervation of the muscles of respiration and plays a supporting role in the control of speech.

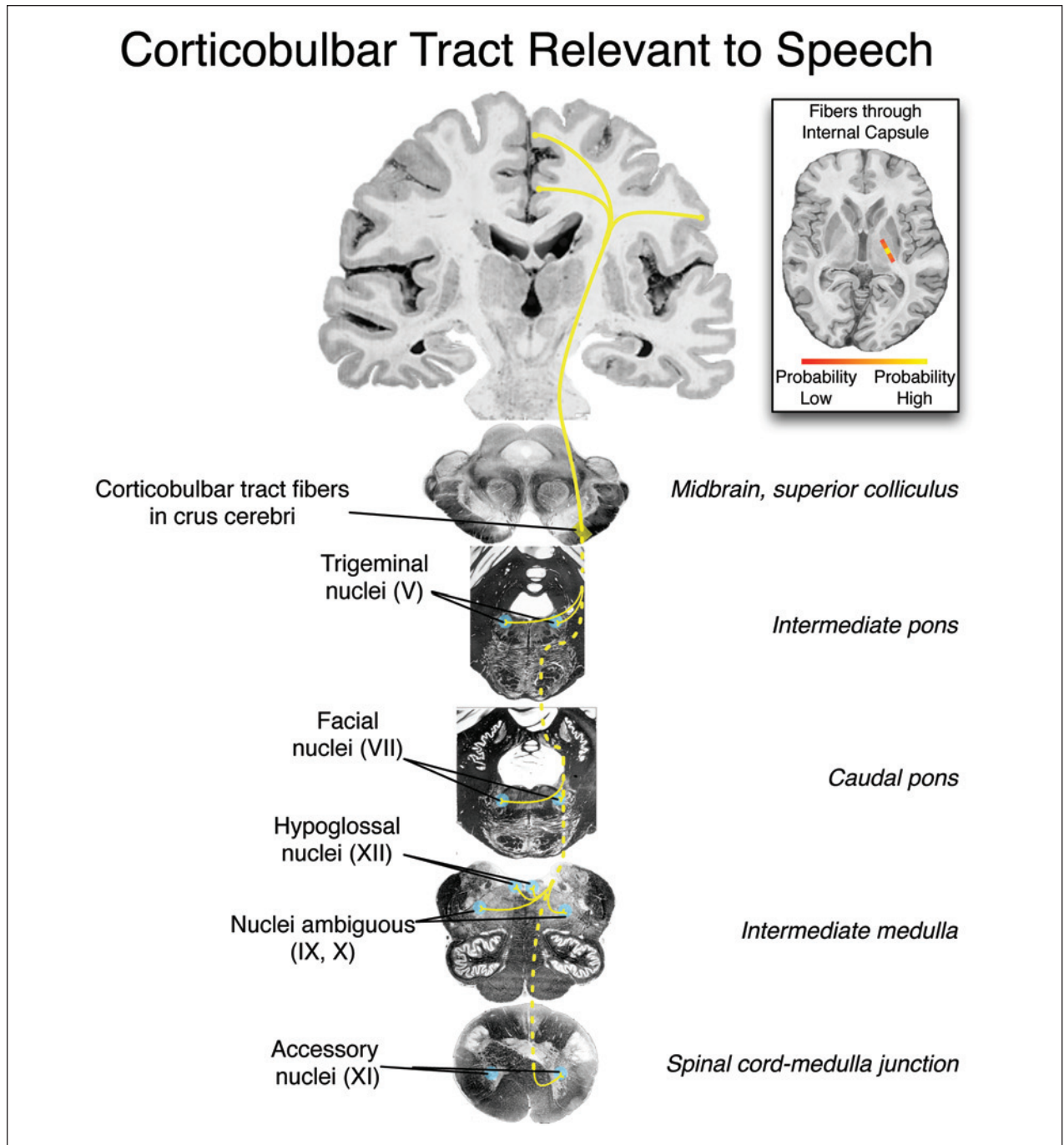


Figure 4. Descending fibers and nuclei of the corticobulbar tract relevant to speech. Inset shows the approximate pathway of fibers through the posterior limb of the internal capsule in axial view. Dotted projections indicate the approximate pathway of the tract through the brainstem.

Neurons forming the CBT originate from the ventral part of the primary sensorimotor cortex, but also from the ventral premotor cortex (PMC) and from the face representation in the supplementary motor (SMA), while neurons forming the CST originate from the dorsal part of the primary sensorimotor, as well as from dorsal PMC and from the leg and hand areas of the SMA. All of these

non-primary regions also project to M1 (Dum and Strick 1991). Importantly, non-primary motor areas also contain a high density of corticospinal and corticobulbar neurons (Picard and Strick 1996), and thus each has the potential to influence the generation and control of movement independently of M1 (Dum and Strick 1991). All pyramidal fibers converge into the internal capsule, with fibers

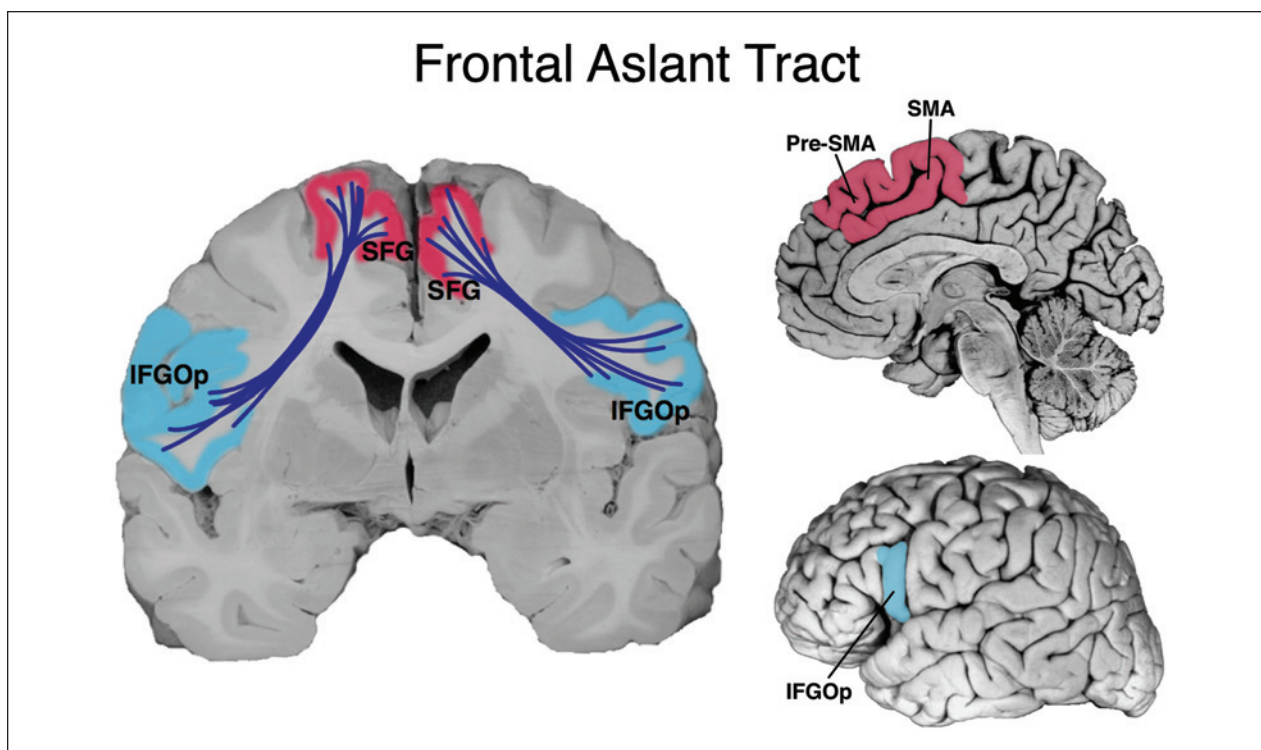


Figure 5. Connections of the frontal aslant tract (FAT) in coronal section, with outline of the inferior frontal and superior frontal origins and terminations in the medial and lateral sagittal views. IFGOp = inferior frontal gyrus, *pars opercularis*; SFG = superior frontal gyrus; SMA = supplementary motor area; Pre-SMA = pre-supplementary motor area.

originating from ventral precentral areas located rostrally to those originating from more dorsal precentral areas. The CBT fibers have a very focused distribution in the internal capsule (Yim and others 2013) and cross at the level of the brainstem, though there is substantial bilateral innervation of the cranial nerve motor nuclei. While these descending tracts serve to send temporally ordered series of motor commands, the patterning and sequencing of these commands results from the interaction of M1 with non-primary motor areas in the frontal lobe.

Association Motor Pathways: The Frontal Aslant Tract

Another potentially important pathway for the production of language has been identified recently based on tractography studies conducted in humans, and termed the “frontal aslant tract” (FAT; Catani and others 2012). The FAT connects the left SMA/pre-SMA to the most posterior part of the inferior frontal gyrus (Fig. 5). However, there is some uncertainty regarding the precise origin of the FAT. Various studies have shown that the FAT originates from the superior frontal gyrus (Lawes and others 2008), the posterior SMA (Oishi and others 2008), and the pre-SMA (Ford and others 2010). In the latter study, a connection between SMA and posterior inferior frontal gyrus was also found, but only in ~40% of participants. In a

recent DTI study (Catani and others 2012), the FAT was found to originate from both the pre-SMA and SMA, though another study from the same group found it to originate from both the pre-SMA and a more lateral site in the SFG (Catani and others 2013). A better understanding of the origin of the FAT is key to understanding its function. Indeed, the pre-SMA and SMA proper, from which the FAT originates, are anatomically and functionally distinct. While the pre-SMA is usually considered a prefrontal region, the SMA is a non-primary motor area (Picard and Strick 1996). Furthermore, only the SMA contributes to the pyramidal system (Dum and Strick 1991), and only the pre-SMA is connected to the prefrontal cortex (Luppino and others 1994). One recent study has shown that reduced verbal fluency in patients with the non-fluent variant of primary progressive aphasia was associated with damage to the FAT (Catani and others 2013). However, given the uncertainty regarding the origin of the FAT, its specific functions remain to be clarified, and could include contributions to wide range of processes relevant to speech, from cognitive control to response selection, initiation, and sequencing.

Subcortical Pathways: Anatomy and Function

While the planning and execution of speech relies on intra-lobar and descending pathways, it also depends on

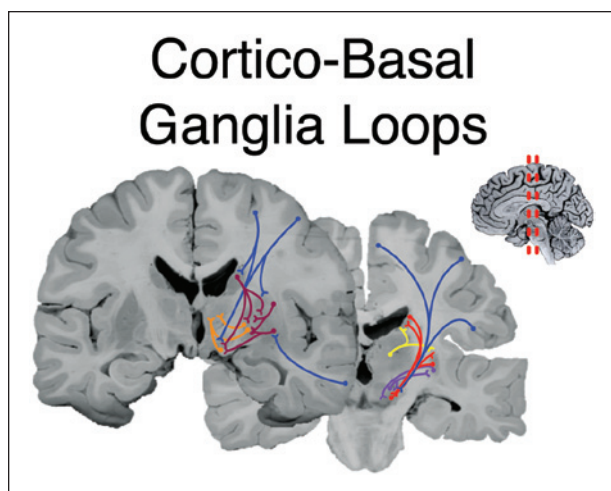


Figure 6. Cortico-basal ganglia-cortical loops. Specific regions of the cortex project topographically through the basal ganglia, to the thalamus, and then back to cortex. The substantia nigra, subthalamic nucleus, and dorsal striatum (caudate and putamen) receive projections topographically from frontal, parietal, and temporal cortex (blue). Fibers from the striatum project to the globus pallidus (external and internal segments; GPe and GPi, respectively) and substantia nigra (reticular part) via the lenticulonigral tract (maroon). The substantia nigra (compact part) sends dopaminergic fibers back to the striatum via the nigrostriatal tract (red). The striatum also receives inputs from the intralaminar nuclei of the thalamus (yellow). The GPe sends efferents and receives afferents from the subthalamic nucleus (purple) via the subthalamic fasciculus. The GPe and GPi send fibers to the thalamus via the ansa lenticularis and lenticular fasciculus (orange). The thalamo-cortical paths are not shown in the figure to reduce clutter. Based on Woolsey TA, Hanaway J, Gado MH. 2007. *The brain atlas: a visual guide to the human central nervous system*. Hoboken, NJ: Wiley.

the integrity of cortico-striatal pathways, particularly the motor and associative cortico-striatal loops (Civier and others 2013; Fig. 6). While the existence of segregated cortico-striatal circuits is known for quite some time in non-human primates, the existence of such organization in humans was only recently demonstrated using DTI (Lehéricy and others 2004; Schmahmann and Pandya 2008). Primary and non-primary motor areas connect to the posterior third of the striatum (particularly the posterior putamen). The striatal fibers leave the cerebral cortex, intermingling with the association fibers emanating from these cortical regions early in their course, to travel via the external capsule. The fibers target the putamen and caudate nuclei, and from there, connections are established with the external and internal pallidum, subthalamic nucleus and ventrolateral thalamic nuclei. The ventrolateral thalamic nuclei project back to the primary and non-primary cortical motor areas, forming the motor component of the cortico-striatal circuit. The pre-SMA, in contrast, along with

prefrontal cortex, connects to more anterior parts of the striatum also via the external capsule. From there, these regions target the internal pallidum, and the ventral anterior thalamic nuclei, which in turn projects back to these same cortical areas, forming the associative cortico-striatal loop that is also implicated in cognitive processes. Both loops are important for producing language, in particular for the selection and temporal ordering of speech movements (Argyropoulos and others 2013). The importance of cortico-striatal loops is shown by findings that damage to the basal ganglia causes difficulties starting, stopping, or sustaining speech movements (Speedie and others 1993), as well as abnormal rate, regularity, and temporal ordering of speech movements (Volkman and others 1992).

The connectivity of the cerebellum is also relevant to understand speech functions (Fig. 7). The cerebellum has two input pathways (inferior and middle cerebellar peduncle) and one output pathway (superior cerebellar peduncle). The input pathway originating in the cortex is the cortico-ponto-cerebellar pathway. Almost all the cortico-ponto-cerebellar fibers cross the midline in the basal pons and terminate in the contralateral half of the cerebellum. The cerebellum itself projects to primary and non-primary motor areas and to the prefrontal cortex (including the pre-SMA) through projections from the cerebellar dentate nucleus via the ventrolateral nucleus of the thalamus, which projects to the contralateral primary and non-primary motor areas and PFC (Salmi and others 2010). These pathways together form a set of cortical-cerebellar-cortical loops involved in the control of actions, including speech. The role of the cortical-cerebellar loop in the control of motor aspects of language appears to be related to the automatization and optimization of speech (Schmahmann and Pandya 2008). Damage to the cerebellum often leads to ataxic dysarthria in which speech is slow, slurred and disjointed, and present with difficulty in concatenating (sequencing) syllable strings into coarticulated speech sequences (Ackermann 2008).

Summary of the Motor Speech Stream

In sum, the production of language is a complex, redundant and heavily regulated system with multiple interconnected cortical sites in the frontal lobe, modulation at all levels (motor, premotor, prefrontal levels) through several cortico-subcortical loops involving the basal ganglia and the cerebellum. In addition, more recent research has revealed potentially important cortical long association fiber pathways that may contribute to speech production. Much remains to be discovered regarding the anatomy and specific functions of each of the components of the motor language network.

Cortico-Cerebello-Cortical Loops

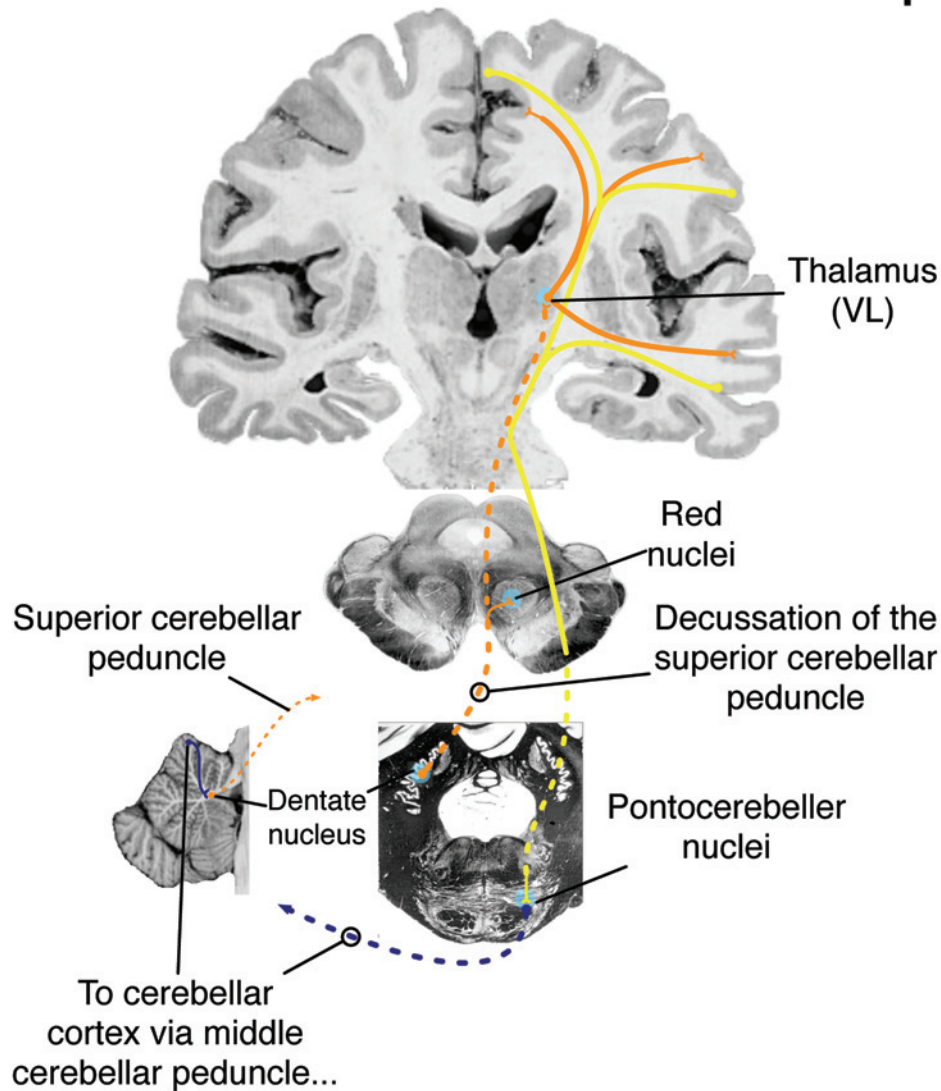


Figure 7. Cortico-cerebello-cortical loops. Descending cortico-ponto-cerebellar fibers target cerebellar nuclei in the pons. These nuclei send crossed projections to the cerebellar cortex via the middle cerebellar peduncle. Purkinje neurons of the cerebellar cortex project to subcortical cerebellar nuclei (the largest of which is the dentate nucleus). These nuclei send crossed projections to the ventrolateral (VL) nucleus of the thalamus, which then project to the cortex. Dotted projections indicate approximate pathway of the tract through the brainstem.

Conclusions

Great progress has been made in defining more precisely the neurobiology of language in the human brain. The classical language model is quickly being replaced with more comprehensive models influenced by advances in neuroimaging methodologies, which have revealed a far more distributed cortical and subcortical network for the processing and production of

language. The emerging framework going forward is one that emphasizes processing streams of particular functional regions anchored by long-association fiber pathways and cortico-subcortical projections. We have reviewed the connective anatomy of three putative processing streams—dorsal, ventral, and motor—and expect that our understanding of language neurobiology will continue to expand rapidly in the coming decades.

Declaration of Conflicting Interests

The author(s) declared no potential conflicts of interest with respect to the research, authorship, and/or publication of this article.

Funding

The author(s) disclosed receipt of the following financial support for the research, authorship, and/or publication of this article: This work was supported by a grant from the Natural Sciences and Engineering Research Council of Canada (NSERC, Discovery Grant: "Neural bases of speech production: contribution of common action control mechanisms," 2013-2018) to PT.

References

- Ackermann H. 2008. Cerebellar contributions to speech production and speech perception: psycholinguistic and neurobiological perspectives. *Trends Neurosci* 31:265–72.
- Agosta F, Galantucci S, Canu E, Cappa SF, Magnani G, Franceschi M, and others. 2013. Disruption of structural connectivity along the dorsal and ventral language pathways in patients with nonfluent and semantic variant primary progressive aphasia: A DT MRI study and a literature review. *Brain Lang*. Epub Jul 25.
- Ardila A. 2010. A review of conduction aphasia. *Curr Neurol Neurosci Rep* 10:499–503.
- Argyropoulos GP, Tremblay P, Small SL. 2013. The neostriatum and response selection in overt sentence production: an fMRI study. *Neuroimage* 82:53–60.
- Bernal B, Altman N. 2010. The connectivity of the superior longitudinal fasciculus: a tractography DTI study. *Magn Reson Imaging* 28:217–25.
- Bernal B, Ardila A. 2009. The role of the arcuate fasciculus in conduction aphasia. *Brain* 132:2309–16.
- Bernal B, Rey G, Dunoyer C, Shanbhag H, Altman N. 2010. Agenesis of the arcuate fasciculi in congenital bilateral perisylvian syndrome: a diffusion tensor imaging and tractography study. *Arch Neurol* 67:501–5.
- Brauer J, Anwender A, Perani D, Friederici AD. 2013. Dorsal and ventral pathways in language development. *Brain Lang*. Epub May 1.
- Breier JI, Hasan KM, Zhang W, Men D, Papanicolaou AC. 2008. Language dysfunction after stroke and damage to white matter tracts evaluated using diffusion tensor imaging. *AJNR Am J Neuroradiol* 29:483–7.
- Brown EC, Jeong JW, Muzik O, Rothermel R, Matsuzaki N, Juhász C, and others. 2013. Evaluating the arcuate fasciculus with combined diffusion-weighted MRI tractography and electrocorticography. *Hum Brain Mapp*. Epub Aug 24.
- Catani M, Thiebaut de Schotten M. 2012. *Atlas of human brain connections*. New York: Oxford University Press.
- Catani M, Jones DK, Donato R. 2003. Occipito-temporal connections in the human brain. *Brain* 126:2093–107.
- Catani M, Jones DK, ffytche DH. 2005. Perisylvian language networks of the human brain. *Ann Neurol* 57:8–16.
- Catani M, Dell'acqua F, Vergani F, Malik F, Hodge H, Roy P, and others. 2012. Short frontal lobe connections of the human brain. *Cortex* 48:273–91.
- Catani M, Mesulam MM, Jakobsen E, Malik F, Martersteck A, Wieneke C, and others. 2013. A novel frontal pathway underlies verbal fluency in primary progressive aphasia. *Brain* 136(Pt 8):2619–28.
- Civier O, Bullock D, Max L, Guenther FH. 2013. Computational modeling of stuttering caused by impairments in a basal ganglia thalamo-cortical circuit involved in syllable selection and initiation. *Brain Lang* 126:263–78.
- De Witt Hamer PC, Moritz-Gasser S, Gatignol P, Duffau H. 2011. Is the human left middle longitudinal fascicle essential for language? A brain electrostimulation study. *Hum Brain Mapp* 32:962–73.
- Déjèrène J. 1901. *Anatomie des centres nerveux*. Paris: Rueff et Cie.
- Duffau H, Capelle L, Sichez N, Denvil D, Lopes M, Sichez JP, and others. 2002. Intraoperative mapping of the subcortical language pathways using direct stimulations: an anatomic-functional study. *Brain* 125(Pt 1):199–214.
- Duffau H, Gatignol P, Denvil D, Lopes M, Capelle L. 2003. The articulatory loop: study of the subcortical connectivity by electrostimulation. *Neuroreport* 14:2005–8.
- Duffau H, Gatignol P, Mandonnet E, Peruzzi P, Tzourio-Mazoyer N, Capelle L. 2005. New insights into the anatomic-functional connectivity of the semantic system: a study using cortico-subcortical electrostimulations. *Brain* 128:797–810.
- Duffau H, Moritz-Gasser S, Mandonnet E. 2013. A re-examination of neural basis of language processing: proposal of a dynamic hodotopical model from data provided by brain stimulation mapping during picture naming. *Brain Lang*. Epub Jul 15.
- Dum RP, Strick PL. 1991. The origin of corticospinal projections from the premotor areas in the frontal lobe. *J Neurosci* 11:667–89.
- Fernández-Miranda JC, Rhoton AL, Alvarez-Linera J, Kakizawa Y, Choi C, de Oliveira EP. 2008. Three-dimensional microsurgical and tractographic anatomy of the white matter of the human brain. *Neurosurgery* 62:989–1026.
- Ford A, McGregor KM, Case K, Crosson B, White KD. 2010. Structural connectivity of Broca's area and medial frontal cortex. *Neuroimage* 52:1230–7.
- Forkel SJ, Thiebaut de Schotten M, Kawadler JM, Dell'acqua F, Danek A, Catani M. 2012. The anatomy of fronto-occipital connections from early blunt dissections to contemporary tractography. *Cortex*. Epub Sep 20.
- Friederici AD, Bahlmann J, Heim S, Schubotz RI, Anwender A. 2006. The brain differentiates human and non-human grammars: functional localization and structural connectivity. *Proc Natl Acad Sci U S A* 103:2458–63.
- Geschwind N. 1970. The organization of language and the brain. *Science* 170:940–4.
- Gil-Robles S, Carvallo A, Jimenez Mdel M, Gomez Caicoya A, Martinez R, Ruiz-Ocaña C, and others. 2013. Double dissociation between visual recognition and picture naming: a study of the visual language connectivity using tractography and brain stimulation. *Neurosurgery* 72:678–86.
- Glasser MF, Rilling JK. 2008. DTI tractography of the human brain's language pathways. *Cereb Cortex* 18:2471–82.
- Griffiths JD, Marslen-Wilson WD, Stamatakis EA, Tyler LK. 2013. Functional organization of the neural language

- system: dorsal and ventral pathways are critical for syntax. *Cereb Cortex* 23:139–47.
- Harrison TC, Murphy TH. 2014. Motor maps and the cortical control of movement. *Curr Opin Neurobiol.* 24:88–94.
- Hickok G, Poeppel D. 2007. The cortical organization of speech processing. *Nat Rev Neurosci* 8:393–402.
- Holland R, Lambon Ralph MA. 2010. The anterior temporal lobe semantic hub is a part of the language neural network: selective disruption of irregular past tense verbs by rTMS. *Cereb Cortex* 20:2771–5.
- Holl N, Noblet V, Rodrigo S, Dietemann JL, Mekhbi MB, Kehrli P, and others. 2011. Temporal lobe association fiber tractography as compared to histology and dissection. *Surg Radiol Anat* 33:713–22.
- Jürgens U. 2002. Neural pathways underlying vocal control. *Neurosci Biobehav Rev* 26:235–58.
- Kho KH, Indefrey P, Hagoort P, van Veelen CW, van Rijen PC, Ramsey NF. 2008. Unimpaired sentence comprehension after anterior temporal cortex resection. *Neuropsychologia* 46:1170–8.
- Lau EF, Phillips C, Poeppel D. 2008. A cortical network for semantics: (De)constructing the N400. *Nat Rev Neurosci* 9:920–33.
- Lawes IN, Barrick TR, Murugam V, Spierings N, Evans DR, Song M, and others. 2008. Atlas-based segmentation of white matter tracts of the human brain using diffusion tensor tractography and comparison with classical dissection. *Neuroimage* 39:62–79.
- Lehéricy S, Ducros M, Van de Moortele PF, Francois C, Thivard L, Poupon C, and others. 2004. Diffusion tensor fiber tracking shows distinct corticostriatal circuits in humans. *Ann Neurol* 55:522–9.
- Ludwig E, Klingler J. 1956. *Atlas cerebri humani*. Boston, MA: Little, Brown.
- Luppino G, Matelli M, Camarda R, Rizzolatti G. 1994. Corticospinal projections from mesial frontal and cingulate areas in the monkey. *Neuroreport* 5:2545–8.
- Makris N, Kennedy DN, McInerney S, Sorensen AG, Wang R, Caviness VS Jr, and others. 2005. Segmentation of subcomponents within the superior longitudinal fascicle in humans: a quantitative, in vivo, DT-MRI study. *Cereb Cortex* 15:854–69.
- Makris N, Pandya DN. 2009. The extreme capsule in humans and rethinking of the language circuitry. *Brain Struct Funct* 213:343–58.
- Makris N, Papadimitriou GM, Kaiser JR, Sorg S, Kennedy DN, Pandya DN. 2009. Delineation of the middle longitudinal fascicle in humans: a quantitative, in vivo, DT-MRI study. *Cereb Cortex* 19:777–85.
- Makris N, Preti MG, Asami T, Pelavin P, Campbell B, Papadimitriou GM, and others. 2013a. Human middle longitudinal fascicle: Variations in patterns of anatomical connections. *Brain Struct Funct* 218:951–68.
- Makris N, Preti MG, Wassermann D, Rathi Y, Papadimitriou GM, Yergatian C, and others. 2013b. Human middle longitudinal fascicle: segregation and behavioral-clinical implications of two distinct fiber connections linking temporal pole and superior temporal gyrus with the angular gyrus or superior parietal lobule using multi-tensor tractography. *Brain Imaging Behav* 7:335–52.
- Maldonado IL, Champfleur NM, Velut S, Destrieux C, Zemmoura I, Duffau H. 2013. Evidence of a middle longitudinal fasciculus in the human brain from fiber dissection. *J Anat* 223:38–45.
- Maldonado IL, Moritz-Gasser S, de Champfleur NM, Bertram L, Moulinié G, Duffau H. 2011. Surgery for gliomas involving the left inferior parietal lobule: new insights into the functional anatomy provided by stimulation mapping in awake patients. *J Neurosurg* 115:770–9.
- Mandonnet E, Nouet A, Gatignol P, Capelle L, Duffau H. 2007. Does the left inferior longitudinal fasciculus play a role in language? A brain stimulation study. *Brain* 130(Pt 3):623–9.
- Marchina S, Zhu LL, Norton A, Zipse L, Wan CY, Schlaug G. 2011. Impairment of speech production predicted by lesion load of the left arcuate fasciculus. *Stroke* 42:2251–6.
- Martino J, Brogna C, Robles SG, Vergani F, Duffau H. 2010a. Anatomic dissection of the inferior fronto-occipital fasciculus revisited in the lights of brain stimulation data. *Cortex* 46:691–9.
- Martino J, Vergani F, Robles SG, Duffau H. 2010b. New insights into the anatomic dissection of the temporal stem with special emphasis on the inferior fronto-occipital fasciculus: implications in surgical approach to left mesio-temporal and temporoinsular structures. *Neurosurgery* 66:4–12.
- Martino J, De Witt Hamer PC, Berger MS, Lawton MT, Arnold CM, de Lucas EM, and others. 2013. Analysis of the sub-components and cortical terminations of the perisylvian superior longitudinal fasciculus: a fiber dissection and DTI tractography study. *Brain Struct Funct* 218:105–21.
- Menjot de Champfleur N, Lima Maldonado I, Moritz-Gasser S, Machi P, Le Bars E, and others. 2013. Middle longitudinal fasciculus delineation within language pathways: a diffusion tensor imaging study in human. *Eur J Radiol* 82:151–7.
- Moritz-Gasser S, Herbet G, Duffau H. 2013. Mapping the connectivity underlying multimodal (verbal and non-verbal) semantic processing: a brain electrostimulation study. *Neuropsychologia* 51:1814–22.
- Oishi K, Faria AV, van Zijl PCM, Mori S. 2011. *MRI atlas of human white matter*. San Diego, CA: Academic Press.
- Oishi K, Zilles K, Amunts K, Faria A, Jiang H, Li X, and others. 2008. Human brain white matter atlas: identification and assignment of common anatomical structures in superficial white matter. *Neuroimage* 43:447–57.
- Papagno C, Miracapillo C, Casarotti A, Romero Lauro LJ, Castellano A, Falini A, and others. 2011. What is the role of the uncinate fasciculus? Surgical removal and proper name retrieval. *Brain* 134:405–14.
- Perani D, Saccuman MC, Scifo P, Anwander A, Spada D, Baldoli C, and others. 2011. Neural language networks at birth. *Proc Natl Acad Sci U S A* 108:16056–61.
- Petrides M, Pandya DN. 2009. Distinct parietal and temporal pathways to the homologues of Broca's area in the monkey. *PLoS Biol* 7:e1000170.
- Picard N, Strick PL. 1996. Motor areas of the medial wall: a review of their location and functional activation. *Cereb Cortex* 6:342–53.
- Poeppel D, Emmorey K, Hickok G, Pylkkänen L. 2012. Towards a new neurobiology of language. *J Neurosci* 32:14125–31.

- Rauschecker JP, Scott SK. 2009. Maps and streams in the auditory cortex: nonhuman primates illuminate human speech processing. *Nat Neurosci* 12:718–24.
- Rolheiser T, Stamatakis EA, Tyler LK. 2011. Dynamic processing in the human language system: synergy between the arcuate fascicle and extreme capsule. *J Neurosci* 31:16949–57.
- Salmi J, Pallesen KJ, Neuvonen T, Brattico E, Korvenoja A, Salonen O, and others. 2010. Cognitive and motor loops of the human cerebro-cerebellar system. *J Cogn Neurosci* 22:2663–76.
- Sarubbo S, De Benedictis A, Maldonado IL, Basso G, Duffau H. 2013. Frontal terminations for the inferior fronto-occipital fascicle: anatomical dissection, DTI study and functional considerations on a multi-component bundle. *Brain Struct Funct* 218:21–37.
- Saur D, Kreher BW, Schnell S, Kümmerer D, Kellmeyer P, Vry MS, and others. 2008. Ventral and dorsal pathways for language. *Proc Natl Acad Sci U S A* 105:18035–40.
- Schmahmann JD, Pandya DN. 2006. *Fiber pathways of the brain*. Oxford, England: Oxford University Press.
- Schmahmann JD, Pandya DN. 2008. Disconnection syndromes of basal ganglia, thalamus, and cerebrocerebellar systems. *Cortex* 44:1037–66.
- Seltzer B, Pandya DN. 1984. Further observations on parieto-temporal connections in the rhesus monkey. *Exp Brain Res* 55:301–12.
- Speedie LJ, Wertman E, Ta'ir J, Heilman KM. 1993. Disruption of automatic speech following a right basal ganglia lesion. *Neurology* 43:1768–74.
- Tanabe H, Sawada T, Inoue N, Ogawa M, Kuriyama Y, Shiraishi J. 1987. Conduction aphasia and arcuate fasciculus. *Acta Neurol Scand* 76:422–7.
- Thiebaut de Schotten M, Dell'Acqua F, Valabregue R, Catani M. 2012. Monkey to human comparative anatomy of the frontal lobe association tracts. *Cortex* 48:82–96.
- Turken AU, Dronkers NF. 2011. The neural architecture of the language comprehension network: converging evidence from lesion and connectivity analyses. *Front Syst Neurosci* 5:1–20.
- Volkman J, Hefter H, Lange HW, Freund HJ. 1992. Impairment of temporal organization of speech in basal ganglia diseases. *Brain Lang* 43:386–99.
- Von Der Heide RJ, Skipper LM, Klobusicky E, Olson IR. 2013. Dissecting the uncinate fasciculus: disorders, controversies and a hypothesis. *Brain* 136:1692–707.
- Wang Y, Fernández-Miranda JC, Verstynen T, Pathak S, Schneider W, Yeh FC. 2012. Rethinking the role of the middle longitudinal fascicle in language and auditory pathways. *Cereb Cortex* 23:2347–56.
- Wilson SM, Galantucci S, Tartaglia MC, Rising K, Patterson DK, Henry ML, and others. 2011. Syntactic processing depends on dorsal language tracts. *Neuron* 72:397–403.
- Wong FC, Chandrasekaran B, Garibaldi K, Wong PC. 2011. White matter anisotropy in the ventral language pathway predicts sound-to-word learning success. *J Neurosci* 31:8780–5.
- Yeatman JD, Dougherty RF, Rykhlevskaia E, Sherbondy AJ, Deutsch GK, Wandell BA, and others. 2011. Anatomical properties of the arcuate fasciculus predict phonological and reading skills in children. *J Cogn Neurosci* 23:3304–17.
- Yeterian EH, Pandya DN, Tomaiuolo F, Petrides M. 2012. The cortical connectivity of the prefrontal cortex in the monkey brain. *Cortex* 48:58–81.
- Yim SH, Kim JH, Han ZA, Jeon S, Cho JH, Kim GS, and others. 2013. Distribution of the corticobulbar tract in the internal capsule. *J Neurol Sci* 334:63–8.